

# Port Wine Birthmark

## FAST FACTS

**0.1–0.2%**

of newborns are born with PWB

**~10%**

of patients with forehead PWB have Sturge-Weber syndrome

## WHEN TO REFER

Refer urgently to Hemangioma and Vascular Malformation Center (HVMC) at 513-636-7742 if the face is involved. The HVMC offers multidisciplinary care, including dermatology, neurology, ophthalmology and hematology.

Refer non-urgently to HVMC or local dermatologist who offers PDL if any other red flags are present.

Port wine birthmark (PWB) is a congenital vascular malformation composed of dermal capillaries and postcapillary venules. PWBs are usually unilateral and can occur anywhere on the body. They present as well-defined pink, purple or red patches. Other names for PWB include capillary malformation, nevus flammeus and port wine stain.

These birthmarks are often isolated skin findings but may develop complications and are uncommonly associated with syndromes such as Sturge-Weber that are best treated in multispecialty clinics. PWB can be seen in association with other anomalies such as megacephaly, overgrowth of soft tissue, limbs or digits, and scoliosis in patients with disorders of the PIK3CA-related overgrowth spectrum (PIK3CA).

Simple PWBs not involving the face and without red flags can be monitored by PCPs. Any PWB requiring treatment should be referred to a multispecialty clinic or dermatologist who offers pulsed dye laser (PDL).

## ASSESSMENT

Perform a thorough physical exam including vital signs. Examine the entire skin, mucous membranes, eyes, spine and limbs and conduct a gross neurologic exam.

In the first 6 weeks of life, PWBs may be difficult to distinguish from an infantile hemangioma. PWBs will often fade slightly around this time, while infantile hemangiomas will proliferate. Refer to Infantile Hemangioma CPST for treatment and referral guidance.

Nevus simplex may also mimic PWBs but classically involves the midline glabella, upper eyelids, posterior scalp and lower back. They are less well demarcated than PWBs and fade significantly during the first year of life. Nevus simplex does not require specialty care.

## HISTORY AND PHYSICAL EXAM RED FLAGS

- Bleeding, ulceration, swelling, pain or other symptoms at PWB site
- Involvement of the face, especially the eyelids and/or forehead (may indicate Sturge-Weber syndrome/ocular involvement)
- Multiple PWBs, especially if bilateral
- PWBs associated with limb length or girth discrepancy, scoliosis or lipomas or other congenital anomalies

## MANAGEMENT/TREATMENT

PDL is the preferred treatment for PWB and requires multiple sessions. It should be initiated as early in life as possible for facial PWB to maximize treatment efficacy, decrease need for general anesthesia, decrease potential psychosocial impact and avoid complications. It is needed less urgently for other PWBs.

PDL can be performed under 1 year of age in office without need for general anesthesia. PWBs recalcitrant to PDL may respond to other lasers such as the alexandrite or Nd:YAG.

If you would like additional copies of this tool, or would like more information, please contact the Physician Outreach and Engagement team at Cincinnati Children's.

**For urgent issues or to speak with a pediatric dermatologist on call 24/7, call the Physician Priority Line at 1-888-987-7997.**

# Port Wine Birthmark

**Patient Presents**

**Standard Workup**

Perform a thorough physical exam including vital signs. Examine the entire skin, mucous membranes, eyes, spine and limbs and conduct a gross neurologic exam.

**HISTORY AND PHYSICAL EXAM RED FLAGS**

- Bleeding, ulceration, swelling, pain or other symptoms at PWB site
- Involvement of the face, especially the eyelids and/or forehead (may indicate Sturge-Weber syndrome/ocular involvement)
- Multiple PWBs, especially if bilateral
- PWBs associated with limb length or girth discrepancy, scoliosis or lipomas

**Any Red Flags?**

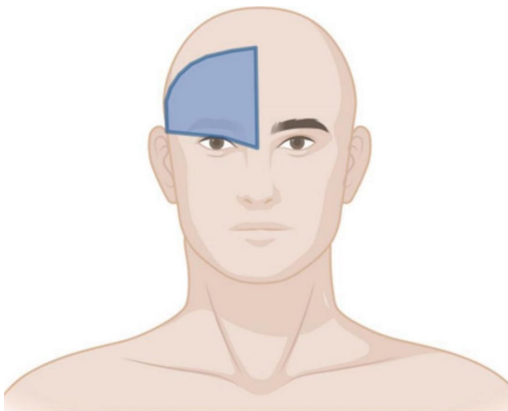
**Yes**

**No**

For PWBs involving the face, refer **urgently** to Hemangioma and Vascular Malformation Center (HVMC)

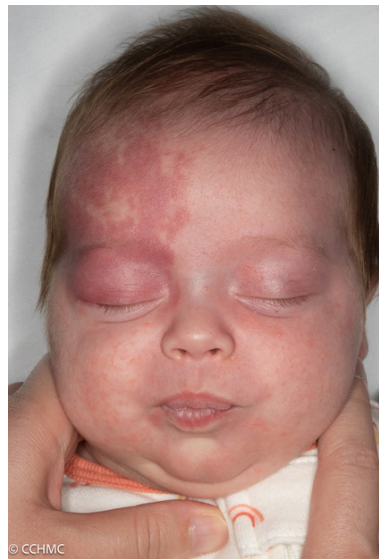If no face involvement but other red flags are present, refer **non-urgently** to HVMC or local dermatologist who offers PDL.

Patient can be monitored by PCP. If concerns for infantile hemangioma (IH), refer to IH Community Practice Support Tool for guidance. Concerns for nevus simplex do not require specialty care.

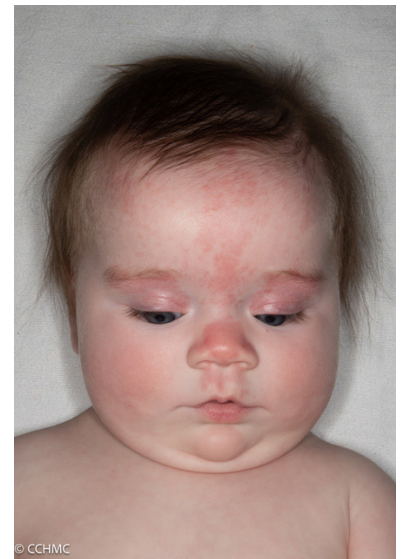

The most reliable cutaneous indicator of Sturge-Weber syndrome is the presence of PWB skin lesions located within the triangular region formed by the midline of the forehead, the outer edge of the eye, and the top of the ear.

Medical illustration credit: *Frontiers in Human Neuroscience*, Nov. 2022



PWB involving the forehead area in a patient with Sturge-Weber syndrome



Extensive nevus simplex involving the glabella, upper eyelids, nose and cutaneous upper lip

For urgent issues, or to speak with the specialist on call 24/7, call the Physician Priority Link® at 1-888-987-7997.